

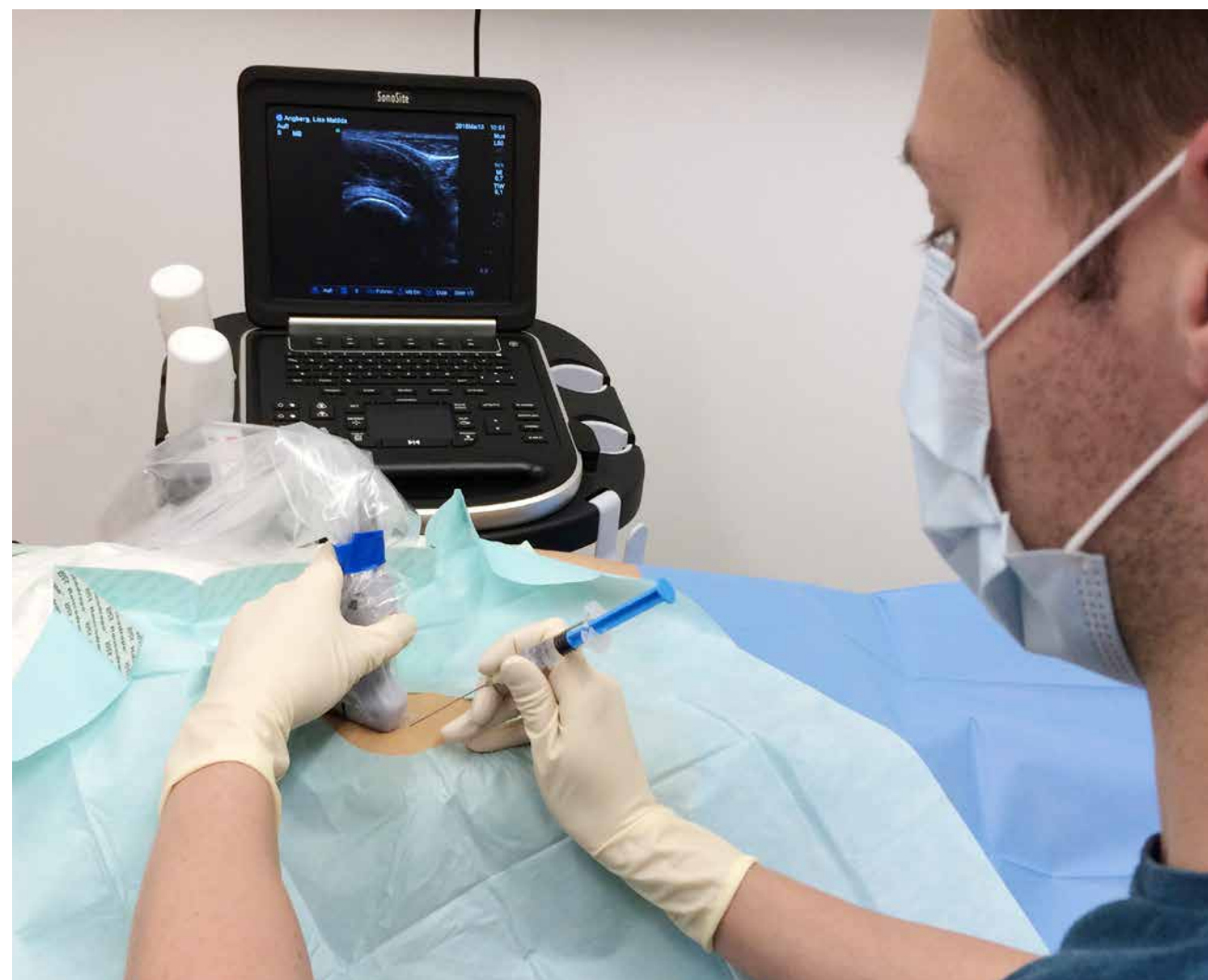
INJECTABLE BLOOD DERIVATIVES

Practical use and combinations for sports injuries

RALF DOYSCHER MD¹ AND MARTIN BARTSCH MD²
¹BORUSSIA MÖNCHENGLADBACH, ²MEVIVA MEDICAL CENTRE BERLIN

The use of injection therapies for sports injuries has had a well-established place in sports orthopaedic practice for many decades. In particular, the use of blood derivatives such as PRP (platelet rich plasma) and BCS (blood clot secretome, formerly ACS, autologous conditioned serum), which has increased in popularity in recent years, is now becoming more common and attracting more scientific attention.

Whereas in our previous article we provided an overview of the main available manufacturing methods and products, it is of course equally important and of interest that we share our experiences with specific use in practice, possible treatment combinations and treatment plans with colleagues and patients.



PIN-POINT APPLICATION, IDEALLY IMAGE-GUIDED

Unlike synthetic products such as corticosteroids, which can also be injected in the area surrounding the target structure but which can still achieve an adequate effect via diffusion and blood circulation (in case of doubt, also via a systemic effect), biological substances have to be injected with a high degree of accuracy at the target site. Thus, it is important not only to establish the correct indication but also to administer the injection using the appropriate technique. While there is no doubting the expertise of many colleagues in also using palpation alone to locate the target structure when administering injections, the nagging question nonetheless remains how often it then turns out in the follow-up imaging procedure that the injection has been misdirected after all. Studies have reported misdirection in up to 50% of cases even in readily palpable structures such as the AC joint and with experienced users [1]. This is why image-guided infiltration procedures such as ultrasound-guided injection (particularly for muscles, tendons and peripheral joints) and image converter, CT or MRI-guided injections (particularly on the spine, such as PRT) became established early on. Some manufacturers now provide high-quality courses with hands-on workshops using models and human specimens.

The ideal treatment of patients directly after injection is also largely un-researched. In daily clinical practice we have observed that allowing patients to lie or sit for 10–15 minutes with no loading of the treated area immediately after BCS or PRP injection in muscles or tendons can help increase tolerance and efficacy. This, in our view, may be due to the conversion of fibrin in the tissue, which continues for a short time after administration and may help retain the infiltrate at the administration site. If, on the other hand, the tissue is loaded immediately after injection, movement

and tissue tension may squeeze the still completely liquid infiltrate out of the tissue or distribute it widely.

THE CORRECT INDICATION FOR THE CORRECT PROCEDURE – EMPIRICAL DATA/CLINICAL EXPERIENCE

Unfortunately, there are virtually no substantive comparative studies of the use of different blood derivatives in sports orthopaedic injection therapy. Only the outcome of different studies on individual products can be compared. This, unfortunately, does not allow any comparative recommendations to be made as to what procedure is preferable for what indication – for the time being at least we must rely on our own or shared clinical experience. For example, in the experience of the authors the use of PRP with a high proportion of platelets and fibrin has proved to be of value particularly in the treatment of cases where the aim is to induce connective tissue synthesis, such as in fascia and tendon injuries, and to heal degenerative defects, e.g. in the central tendon area in advanced patellar tip syndrome and achillodynia. We have also observed in clinical practice that combined treatment with Traumeel or Zeel appears to alleviate tissue reactions particularly in muscle injuries and may therefore be a useful adjunct, e.g. when placing injection cannulas. The anti-inflammatory effect of BCS is also apparently of particular clinical value in more minor injuries and irritation in the tendon bed and in joints, e.g. secondary to arthritic changes. In this instance, initial deterioration with swelling, erythema and increased pain have been found to be less common than with platelet-rich blood derivatives. We have also time and again observed the same with facet joint infiltration and periradicular therapy (PRT) on the spine.

COMBINING TREATMENTS TO ACHIEVE SUCCESS

However careful one might be in esta-

blishing the indication and the appropriate injection technique, one thing is still clear – injection therapy alone generally does not result in the healing and resolution of underlying causes in injuries and overuse damage. It must be integrated as a useful and essential element in a multimodal treatment concept. Concomitant physiotherapy with manual therapy and physical exercises as well as local physical treatments such as heat therapy, ultrasound, deep heat treatment, electrotherapy etc. have become virtually indispensable in competitive sport. It is also important to perform functional analysis of statics problems and of hypomobility in the function of ascending and descending joint and muscle chains and to assess potential visceral and segmental components. One specific treatment combination that has proved to be of value in clinical practice is the alternating use of extracorporeal shock wave therapy (ESWT – focused and/or radial, depending on the indication) and/or high energy laser with injection therapy (see illustration). Just as important, but equally little researched, is the sequencing and timing of the individual treatment elements. For example, in our clinical experience an alternating approach has proved to be of value, with initial shockwave and laser treatment followed three or four days later by injection, once the treated tissue has recovered a little. After a further four to five days, the next session of shock wave and/or laser therapy can be given. The cycle should be repeated three to five times, depending on the indication. However, with such intensive treatment, a noticeable improvement is often already evident after the second cycle. It is essential that the timing and number of repeat sessions are individually adjusted to the indication, patient acceptance and any local reactions. It is particularly important that the patient is fully informed about the treatment course, possible symptoms such as pain during and after injection,

RALF DOYSCHER MD



has been the permanent team doctor at Borussia Mönchengladbach since 2018. Before that, he worked as an orthopaedic and trauma surgery specialist in various departments of the Charité Hospital Berlin, working at the end of his time there in the Department of Sports Medicine and Conservative Sports Orthopaedics. He was also the team doctor at 1. FC Union Berlin and the association doctor of the German Athletics Association (DLV) and the German Bobsleigh, Luge and Skeleton Federation (BSD).

MARTIN BARTSCH MD

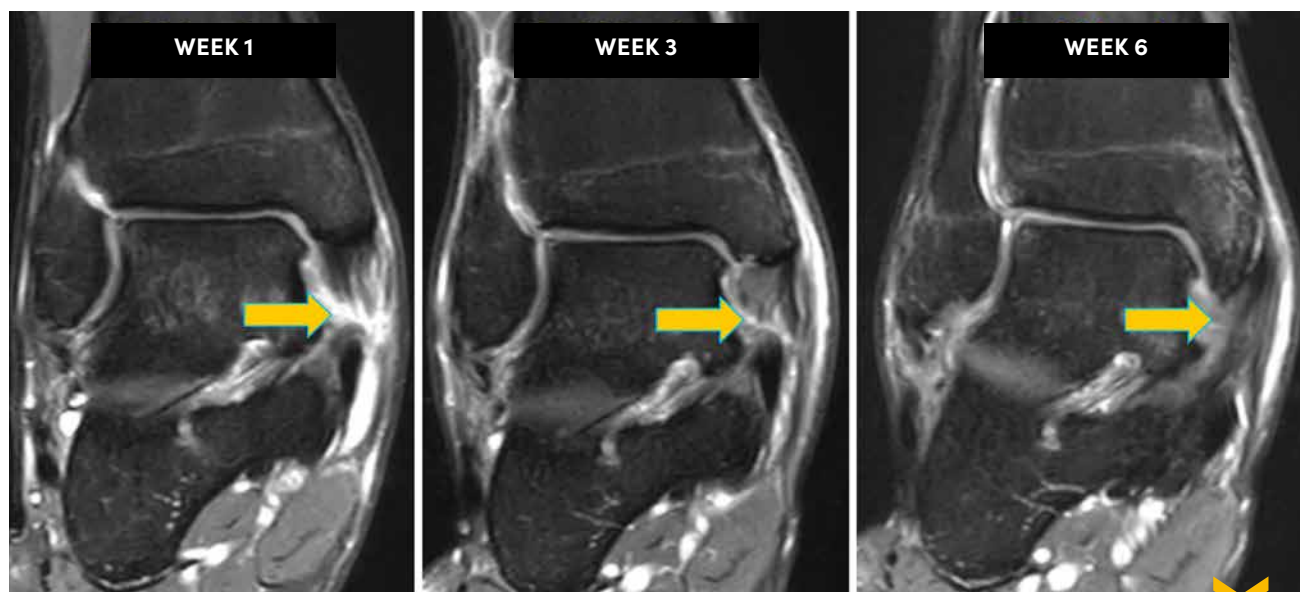


initially trained as a specialist in orthopaedics and trauma surgery at the Charité University Hospital Berlin before then further qualifying as a specialist in sports medicine in the Department of Sports Medicine of the same hospital. He has acquired extensive experience in the support of top-level athletes through working with several Berlin sports associations and also as team doctor of the German Olympic team at the 2018 Winter Olympic Games. He is now resident orthopaedic consultant at meviva. His work covers all aspects of conservative orthopaedics and sports medicine.

potential tissue irritation (initial deterioration), the need for multiple sessions and concomitant physiotherapy and guidance on exercise activities.

CONCLUSION

- » Advice for the use of BCS and PRP in clinical practice:
- » reliable injection technique, ideally ultrasound or MRI-guided
- » no loading of the treated area, e.g. with the patient lying or sitting for 15 minutes after the injection (to allow fibrin clots to form)
- » where applicable, cool the injection site when symptoms are severe; where possible,
- » avoid using NSAIDs and local anaesthetics
- » always use as one element of multimodal treatment with local applications and exercise activities to ensure long-term success
- » combined ESWT and physical procedures such as high energy laser have proved
- » effective in clinical practice



MRI follow-up scans of a complete deltoid ligament tear in the ankle in a 24-year-old athlete receiving conservative treatment with BCS injections, ESWT and laser.