



Research Article

A Combination of Tisseel Fibrin Glue and Orthokine ACS improves Knee Meniscus Injury Treatment and helps Avoid Surgery 4-year follow-up Archive Study

Rudolf W Strümper*, Julio Reinecke, Johann W Rechmeier, René Schilling, Peter Wehling

Privatpraxis Orthopädie im Rheinauhafen, Cologne, Germany

*Corresponding author: Rudolf W Strümper, Privatpraxis Orthopädie im Rheinauhafen, Cologne, Germany.

Citation: Strümper RW, Reinecke J, Rechmeier JW, Schilling R, Wehling P (2021) A Combination of Tisseel Fibrin Glue and Orthokine ACS improves Knee Meniscus Injury Treatment and helps Avoid Surgery 4-year follow-up Archive Study. Sports Injr Med 10172. DOI: 10.29011/2576-9596.110172

Received Date: 05 December, 2021; **Accepted Date:** 16 December, 2021; **Published Date:** 23 December, 2021

Abstract

Background: The routine use of biological therapies with potentially regenerative augmentation of tissue repair is reality. Techniques applied include stem cells, platelet preparations, recombinant growth factors and autologous conditioned serum (ACS), partly in combination with other techniques such as matrices, surgery and fibrin glue. ACS contains blood cell released factors which have the potential to improve tissue repair or regeneration.

Aim: Retrospective analysis of clinical data of intra-articular fibrin glue fixation combined with ACS injections in clinical cases of routine outpatients presenting with knee pain and MRI- confirmed meniscal defects.

Methods: An established intra-articular injection treatment method for osteoarthritis involving autologous conditioned serum (ACS) was routinely employed. ACS is prepared from patient's blood subjected to extended coagulation at physiologic temperature. The serum supernatant is separated from cellular components by centrifugation. A dedicated medical device (EOT[®]II, Orthokine) is employed. Outpatients (n = 170), with lesions of the knee meniscus of heterogeneous genesis, severity and duration, were treated with fibrin glue to fixate the tissue injury followed by weekly intra-articular ACS injections (up to 6). Average age was 55.29 years (SD ±12.48) (range 14-84). Follow ups extend from baseline up to 4 years. Clinical effects are documented by WOMAC score at baseline, 6 weeks and yearly intervals. All analyses were performed from archived patient files.

Results: 8 of 170 patients chose surgical treatment of the meniscal injury. 162 patients avoided surgery during the period analyzed. Mean WOMAC global score improved from 34.62 (SD ± 18.48) to 13.18 (SD ± 9.52) (p = 0.0015) at 4 years.

Conclusion: This archive evaluation of a heterogeneous real-life cohort suggests that intra-articular fixation of meniscus injuries with fibrin glue followed by 4 i.a. ACS/BCS injections improves knee symptoms associated with meniscal injury. Controlled studies of Fibrin Glue + ACS treatment for meniscal lesions are advocated.

Introduction

Knee injury is a major risk factor for the development of knee OA. The OA risk after knee injury goes up 4-6- fold [1]. Numbers of acute meniscus injuries per 1000 inhabitants per year range from 0.5 to 0.7. This relates to stable knees. Instable knees' percentage goes up to 96 % depending on the case.

Meniscal tears are a common knee injury often related to sports activities. Among US high school athletes more than 20 % of all knee injuries are meniscus injuries. Other publications looking at different cohorts find > 10 % rates [2,3]. Knee injuries in general are significantly more likely to be treated with surgery than all other injuries. Hence, most meniscal injuries tend also to be treated surgically (> 60 %) [4]. Interestingly [2] points out that a vast number of sports injuries may not be treated appropriately. Since then (2000) this may have improved, advanced imaging techniques have improved in quality and become more easily accessible [5].

The 2019 ESSKA meniscus consensus [6] recommends surgery as early as possible when repair is required, preservation of the meniscus being the main intention of therapy by surgical repair. Biological augmentation (e.g. ACS, PRP, Stem Cells) was not embraced for lack of consistent evidence.

Nonetheless ESSKA published an Instructional Course Lecture Book featuring a chapter on Biological Therapies in Orthopedics and Sports Medicine [7]. This emphasizes the fact that there is high interest in biologically augmented meniscus repair.

Preservation of the meniscus has been attempted with locally applied fibrin glue [8]. Limited evidence exists for the use of autologous fibrin clots [9, 10]. However, these techniques have not been widely adapted in the clinical community. Fibrin glue stability as a "cast" is limited to weeks and the clinical results obviously were not convincing.

Autologous conditioned serum in meniscal tears

We have described a technique using autologous conditioned serum (ACS) also known as blood cell secretome (BCS) as augmentation to improve symptoms and structural damage related to meniscal tears without prior or concomitant surgery. Oxford knee score (OKS) and Boston Leeds Osteoarthritis Knee Score (BLOKS) were applied in 47 outpatients and documented significant improvements for both scores [11]. Other studies have shown the efficacy of BCS mostly in Osteoarthritis but also in Tendon and Muscle healing (soft tissue) (XXX). ACS/BCS efficacy in Back pain resulting either from Facet OA or nerve root inflammation has also been published (XXX).

Autologous conditioned serum combined with fibrin glue in meniscal tears

In our office so far a total of > 500 cases of injured knee menisci have been treated routinely with fibrin glue locally applied by MRI guidance. Subsequently patients received \pm 4 injections with ACS in weekly succession.

The rationale of this protocol is that Fibrin glue is able to fixate the meniscal wound, bringing the margins in close vicinity. Similar to arthroscopic suturing or pin fixation this aims at facilitating cellular healing. In a damaged joint the milieu often is inflammatory/catabolic. Augmentation with ACS/BCS has shown to be inflammation resolving, to improve healing in a number of experimental and clinical studies with degenerative and acute tissue injuries. It should be capable to support healing more efficiently if the margins of a meniscal wound are kept in close contact long enough to enable cellular contact/healing and junction. This procedure was performed in a setting that avoids anesthesia and surgery. It may be suitable for a subset of injuries where surgical intervention is not strictly necessary.

Materials and Methods

Patients

Outpatient files with a diagnosis of meniscal lesions who had undergone Tisseel plus Orthokine BCS treatment were included in this archive study. All patients had pain, effusion and loss of function of the index knee before treatment.

Data were obtained in compliance with German law and the Declaration of Helsinki, and the authorized ethical committee cleared this retrospective study (U1111-1268-5097, No 276/2021) for the period 2016-2020. Patient anonymity has been carefully protected in the analysis and data analysis. This study meets the ethical standards of the journal. 170 cases of which full score documentation were available and included in this analysis.

ACS/BCS

ACS/BCS was prepared with venous blood drawn with the Orthokine device (EOT[®] II-syringe, Orthogen Lab Services, Germany), which contains medical grade glass spheres. Patients' blood was subjected to extended coagulation in the device for 6 hours at 37 °C. Serum was then recovered by centrifugation and injected into the patient's joints at weekly intervals. The conditioned, cell-free serum is rich in Growth Factors IGF, TGF β , EGF, FGF, PDGF and Cytokines IL-1Ra and smaller amounts of IL-1 β , IL-6, TNF α [33].

Tisseel

The fibrin adhesive system (Tisseel; Baxter Deutschland GmbH, Germany) is composed of solutions A and B. Solution A is made up of purified fibrinogen and aprotinin. Solution B includes thrombin and CaCl₂. It is applied via a double syringe and the 2 components only mix right at the tip of the cannula.

MRI

MRI Airis Vento (Hitachi) is an open device with coils that allow interventional access. Routinely the following sequences are used.

T1	SAG	(SE)
STIR	SAG	(FIR)
WFS PD AX (FatSepFSE)		
3DT1	AX	(RSSG)
STIR	COR	(FIR)
T1	COR	(SE)
PD/T2 SAG (FSE)		

Procedure

The intervention for the application of the fibrin glue takes place in the prone position of the patient with positioning of the intervention coil at the knee joint. After extensive disinfection of the target area and sterile draping, the personnel are equipped with surgical gowns, sterile gloves, surgical masks and surgical head covers. Local anesthetic (5-10 ml 2% Mepivacain) is injected into the popliteal region. A MRI-qualified injection-needle 22 G x 100 mm (KIM-22/10, ITP GmbH, Bochum, Germany) is introduced into the meniscal injury under local anesthesia. The needle position is checked by short MRI sequences in all planes. When the correct needle position in the meniscus is reached, MRI-grade contrast medium Dotarem (Gd-DOTA) (0.5 - 1 mL) is injected *via* the positioned needle to assess the spread in the joint. When contrast medium appears in or immediately adjacent to the injury on the control MRI sequences the patient is placed in the supine position and the fibrin glue is injected through the same (saline washed) cannula. Passive knee-motion from 0 to 60 degrees is manually applied to avoid any unintended adherences. Fibrin glue reaches full strength by 2 min. After sterile bandage the patient is allowed to stand up. The patient is encouraged to put full weight on the index leg and walk independently to a rest area for 30 min

observation. Patients are encouraged to use crutches on the day of the procedure. After 6 weeks MRI-Control and begin with normal activities and muscle training. ACS/BCS injections (2 mL each) are started at 1 week post Tisseel application and repeated weekly until 4 injections.

Documentation

Standard patient documentation included age, sex, classification and position of meniscus tear, classification of OA status according to Kellgren & Lawrence. Diagnostic MRI was not performed at follow up dates. Cases of injury on both knees were counted as separate cases.

Timepoints of documentation are routinely requested at baseline with follow up 6 weeks, 1, 2, 3 and 4 years. Our clinic setup is not to perform studies, rather to perform therapy on outpatients. Documentation or follow up are dependent on the patients' free decision to comply with regular assessment. In this cohort the first patient started treatment 2016-08-12 and last patient started treatment 2020-05-06. This means that in addition to observed drop outs only a limited number of patients have reached the longer follow ups.

Statistics

The basic idea for this retrospective follow-up study was to generate data for proof-of-concept reasons in the indication knee meniscus injury. On the basis of the present study, new hypotheses can be generated and sample size calculations for future studies performed.

For this reason, the statistical analysis was performed exploratory with descriptive methods. This includes frequency tables, mean, standard deviation and effect size. Since the study is monocentric and therefore not necessarily representative, we omitted inferential statistics in order not to trigger potentially false expectations due to significant p-values. Nevertheless, the very high effect sizes seem to show a clinically relevant impact of ACS, which definitely needs to be revised in future, controlled studies.

Results

This is an open anonymized case series analysis of patients treated in routine practice. We had no incentive for patients to come back and take a WOMAC questionnaire. Also several patients had not reached the later follow up dates. Some cases required repeat interventions due to failed meniscal healing or reinjury (n = 13). 8 of those had a medium size tear, 4 had had previous surgery, 1 had a complex tear.

	Cases available for analysis at baseline
n	170
male/female	108/62
left/right	65/105
LM/MM	22/148
Age	55.29±12.48
K&L grading 0-4	32/81/37/14/6
Treatment repeat 0-3	157/11/1/1

Table 1: Baseline characteristics of patients. LM: lateral injury; MM, medial injury; K&L Kellgren and Lawrence grading. Of 170 cases 13 required repeat treatment for unsatisfactory improvement of symptoms or re-injury.

6 weeks	1 year	2 years	3 years	4 years
106	48	33	30	11

Table 2: Cases available for analysis at the follow-up time points.

WOMAC global, -pain, -stiffness and -function present similar outcomes. There is a substantial improvement of symptoms within 6 weeks post therapy, which remains stable up to 4 years.

Effect size of changes vs baseline are substantial (Figures 1-4). There were no complications during treatment except 1 hematoma. 8 patients required surgery so far.

Figure 1

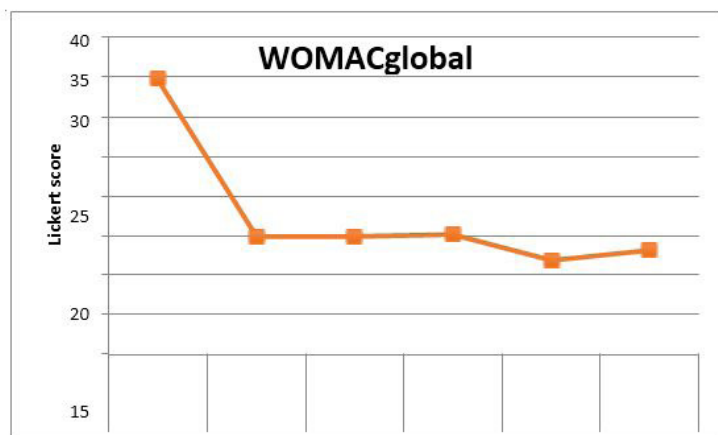
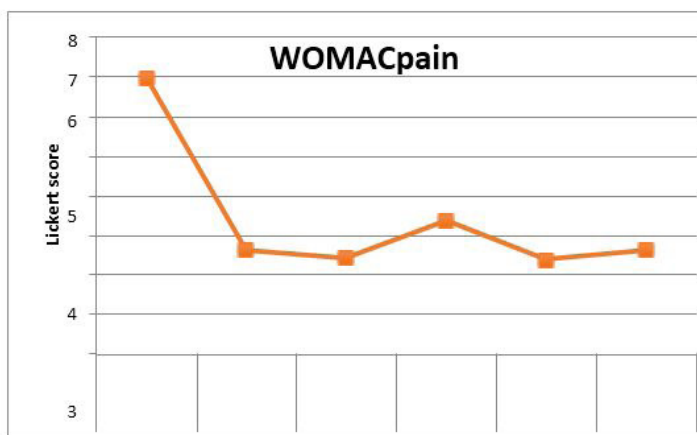
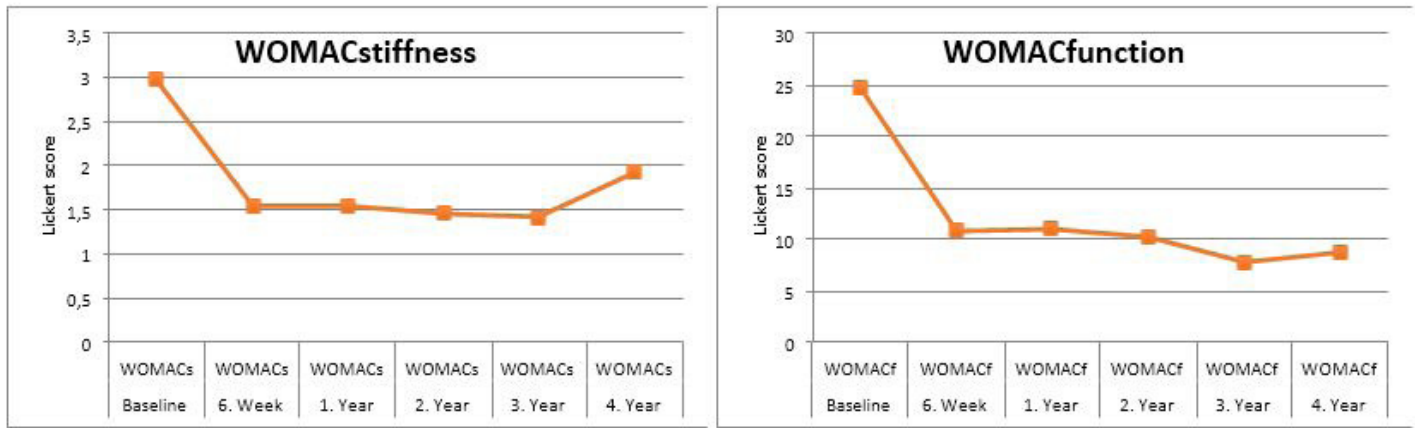


Figure 2



Figures (1 and 2): WOMAC global trajectory over 4 years. Effect sizes (Cohen's d) at 6w 1.04; 1y 1.15; 2y 1.38; 3y 1.53; 4y 2.01; (2) WOMAC pain trajectory over 4 years. Effect sizes (Cohen's d) at 6w 1.06; 1y 1.23; 2y 0.95; 3y 1.3; 4y 2.67.



Figures (3 and 4): WOMACstiffness trajectory over 4 years. Effect sizes (Cohen’s d) at 6w 0.69; 1y 0.95; 2y0.98; 3y 0.91; 4y 0.69; (4) WOMACfunction trajectory over 4 years. Effect sizes (Cohen’s d) at 6w 0.98; 1y 1.05; 2y1.35; 3y 1.51; 4y 1.69.

Patients with meniscus injuries are routinely treated with a fibrin glue cast of the defect. At 1 week after fibrin glue a series of ± 4 ACS/BCS is started in order to augment meniscal healing. WOMAC questionnaires are routinely filled in by out-patients at 1st visit, 6 weeks’ control and at yearly follow up visits. For WOMACglobal and the 3 sub scores pain, stiffness and function we see a uniform drop of mean values. Significant changes vs baseline are marked with * = p < 0.05 ** = p < 0.01

**=p<0.001

	Lateral meniscus	Medial meniscus	total	Follow-up not available
Small tear	3	11	14 (8,2%)	
Medium tear	9	59	68 (40,0%)	
Complex tear	7	51	58 (34,1%)	
Radial tear	0	11	11 (6,5%)	x
Bucket handle	0	1	1 (0,6%)	x
Previous surgery	3	13	16 (9,4%)	
Root tear	0	2	2 (1,2%)	x
Total	22	148	170	

Table 3: Classification of meniscal tears treated in this series.

Location and quality of the injuries treated. 1 bucket handle was treated because it could be repositioned, no follow up was obtained. 2 root tears were treated, no follow up was obtained. From 11 radial tears no follow up was obtained. Small to complex and radial tears did contribute to follow up.

Discussion Interpretation

The data presented here demonstrate that Tisseel fibrin glue casting of meniscal injury followed by BCS/ACS intra-articular injections may improve clinical symptoms as determined by

WOMAC questionnaire. Effect sizes detected are substantial.

Generalization

Meniscus repair surgery has the overarching goal to facilitate tissue regeneration. At present not all cases eligible are treated with repair surgery, and not all cases are eligible for repair surgery. Generally, it is also true that objective healing of a surgically repaired meniscus is often not satisfactory judged from MRI [12-14]. Nonetheless, clinical outcomes often are good. Success of repair surgery is often dependent on skill, location and severity of injury and repair should be performed when possible, particularly

in younger patients [15,16].

Repair of tissues can alternatively be facilitated by Fibrin glue, which can hold wound edges close long enough to allow for cellular re-joining. This has been tested and used in tendon repair for several decades [17-19]. Re-attachment of bony intesional structures have also been described [20]. Bösch et al. found no statistically significant mechanical difference between sutured/glued and sutured only rabbit tendons [21]. Thermann et al. found similar results [22]. Winter and others however confirm that fibrin glue is used routinely in surgery [23-27]. Recently, this approach has been re-discovered [28-31], albeit some -now- with growth factor augmented fibrin glue.

Here, we augmented fibrin glue treatment with autologous factors derived from blood. The advantages of ACS/BCS augmentation are: easy to obtain, 100% autologous, combination of multiple blood borne growth factors known to be involved in tissue regeneration in physiological concentrations and proportions [32,33]. Other factors identified in ACS/BCS include growth factors, cytokines, lipid mediators, extracellular vesicles and components ameliorating oxidative stress. ACS/BCS has a long successful track record for joint and soft tissue injection [33, 34-39] and joint pain reduction [40-45]. It induces stem cell activation *in vitro* [46] and *in vivo* [47], regeneration of tissues (tendon) and promoting intra-articular homeostasis [40, 48-51]. Last but not least, bone lysis in bone tunnels after ACL reconstruction is reduced [52] which fits well with unpublished reports of bone-edema and – fracture improvement. These items are compatible with an ACS/BCS triggered Macrophage M1->M2 shift expressing itself by IL-1Ra upregulation, IL-1b downregulation, Nitric Oxide downregulation, Reactive Oxygen Species downregulation, Hyaluronic Acid Synthase upregulation *in vivo* [51]. A hypothesis of mode of action therefore includes anabolic effects supporting the healing process, reduced oxidative stress and immune cell (e.g. Macrophages) triggered alarm signaling, resulting in pain and function improvement.

A recent review presents an overview of some of the issues of neuropathic pain involvement in musculoskeletal injuries/diseases and regenerative pain medicine [52]. Osteoarthritis pain [53-57] and meniscal injury pain are being discussed in the context of neuropathic characteristics [58,59]. Given the strong evidence of ACS/BCS efficacy in chronic radiculopathy [37,38] it is possible that a component of the data shown here and in [11] result from an amelioration of a neuropathic component.

Perspective

The evidence we present here supports a previous publication that showed good clinical evidence when meniscal injury was treated with ACS/BCS alone and documented by patient based

OKS and MRI based BLOKS scores [11]. However, the data here include no anatomical (e.g. MRI, second look) evidence. But, WOMAC scores confirm clinically advantageous outcomes. First results were presented at the ICRS Focus Meeting in 2018. The technique combines temporary fixation as an alternative to surgical fixation of the injured tissue with anabolic augmentation and promotion of an improved joint homeostasis [51]. Since this is a case collection from clinical practice the data lack the rigor of an RCT. Also, the drop-out rate was substantial. This is mostly attributed to the fact that many patients do not feel the voluntary urge to return for a follow-up appointment. Others started late with the treatment and therefore were not advanced to late follow-up. Last but not least, part of the planned follow-ups fell in the time of the florid COVID-19 epidemic. Therefore, we suggest an adequate clinical study to confirm these promising data.

In our clinic satisfaction with the outcomes of the described procedure is high. More than 500 cases have been treated with only a part of them presenting full documentation (WOMAC). Currently we have 11 four-year follow-ups and are continuing data collection.

The main advantages of this approach include: no surgical risk, no risk from general anesthesia, no irradiation, no thrombosis, no need for hospitalization, meniscus can be preserved, leaks of proteolytic enzymes from damaged meniscus cells are sealed, no immobilization and no muscle atrophy. If the technique fails, no obstacles stand in the way of surgery.

The main disadvantage is that it is not suitable for all meniscus injuries (mainly those with a significant dislocation). The technique is dependent on the spatially correct delivery of the fibrin glue. This is influenced by the injury's localization and its proper imaging. The efficacy of the local anesthesia is also of importance since the Tisseel application inside the injury can be painful.

References

1. Poulsen E, Goncalves GH, Bricca A, Roos EM, Thorlund JB, et al. (2019) Knee osteoarthritis risk is increased 4–6 fold after knee injury - a systematic review and meta-analysis. Br J Sports Med 53: 1454–1463.
2. Corry I, Webb J (2000) Injuries of the sporting knee. Br J Sports Med 34: 395-400.
3. Swenson DM, Collins CL, Best TM, Flanigan DC, Fields SK, et al. (2013) Epidemiology of knee injuries among U.S. high school athletes, 2005/2006-2010/2011. Med Sci Sports Exerc 45: 462-469.
4. Mitchell J, Graham W, Best TM, Collins C, Currie DW, et al. (2016) Epidemiology of meniscal injuries in US high school athletes between 2007 and 2013. Knee Surg Sports Traumatol Arthrosc 24: 715–722.
5. Chien A, Weaver JS, Kinne E, Omar I (2020) Magnetic resonance imaging of the knee. Pol J Radiol 85: e509-e531.

6. Kopf S, Beaufils P, Hirschmann MT, Rotigliano N, Ollivier M, et al. (2019) Management of traumatic meniscus tears: the 2019 ESSKA meniscus consensus. *Knee Surg Sports Traumatol Arthrosc* 28: 1177-1194.
7. Samitier G, Alentorn-Geli E, Filardo G, Aicale R, Tarulli FR, et al. (2020) Biological Therapies in Orthopedics and Sports Medicine. In: Hirschmann M., Kon E., Samuelsson K., Denti M., Dejour D. (eds) ESSKA Instructional Course Lecture Book. Springer, Berlin, Heidelberg. https://doi.org/10.1007/978-3-662-61264-4_28
8. Ishimura M, Ohgushi H, Habata T, Tamai S, Fujisawa Y (1997) Arthroscopic meniscal repair using fibrin glue. Part II: Clinical applications. *Arthroscopy* 13: 558-563.
9. Ra HJ, Ha JK, Jang SH, Lee DW, Kim JG (2013) Arthroscopic inside-out repair of complete radial tears of the meniscus with a fibrin clot. *Knee Surg Sports Traumatol Arthrosc* 21: 2126-2130.
10. van Trommel MF, Simonian PT, Potter HG, Wickiewicz TL (1998) Different regional healing rates with the outside-in technique for meniscal repair. *Am J Sports Med* 26: 446-452.
11. Strümper R (2017) Intra-Articular Injections of Autologous Conditioned Serum to Treat Pain from Meniscal Lesions. *Sport Med Int open* 1: E200-E205.
12. Lee S-S, Ahn JH, Kim JH, Kyung BS, Wang JH (2018) Evaluation of Healing After Medial Meniscal Root Repair Using Second-Look Arthroscopy, Clinical, and Radiological Criteria. *Am J Sports Med* 46: 2661-2668.
13. Willinger L, Herbst E, Diermeier T, Forkel P, Woertler K, et al. (2019) High short-term return to sports rate despite an ongoing healing process after acute meniscus repair in young athletes. *Knee Surg Sports Traumatol Arthrosc* 27: 215-222.
14. Hoffelner T, Resch H, Forstner R, Michael M, Minnich B, et al. (2011) Arthroscopic all-inside meniscal repair-Does the meniscus heal? A clinical and radiological follow-up examination to verify meniscal healing using a 3-T MRI. *Skeletal Radiol* 40: 181-187.
15. Kang DG, Park YJ, Yu JH, Oh JB, Lee DY (2019) A Systematic Review and Meta-Analysis of Arthroscopic Meniscus Repair in Young Patients: Comparison of All-Inside and Inside-Out Suture Techniques. *Knee Surg Relat Res* 31: 1-11.
16. Nepple JJ, Dunn WR, Wright RW (2012) Meniscal repair outcomes at greater than five years: a systematic literature review and meta-analysis. *J Bone Joint Surg Am* 94: 2222-2227.
17. Redaelli C, Niederhäuser U, Carrel T, Meier U, Trentz O (1992) Achillessehnenruptur-Fibrinklebung oder Naht? [Rupture of the Achilles tendon-fibrin gluing or suture?]. *Chirurg* 63: 572-576.
18. Hohendorff B, Siepen W, Spiering L, Staub L, Schmuck T, et al. (2008) Long-term results after operatively treated Achilles tendon rupture: fibrin glue versus suture. *J Foot Ankle Surg* 47: 392-409.
19. Solakoğlu C, Mahiroğulları M, Cakmak S, Tamam C, Kuşkuç M (2010) Fibrin sealant in the treatment of acute ruptures of the Achilles tendon: long-term results. *Eklemler Hastalıkları Cerrahisi* 21: 124-129.
20. Kim HJ, Park JH, Lim HC, Kim BS, Lee JS, et al. (2007) The Healing Effect of Bone Morphogenetic Protein with Fibrin Glue on an Injury of the Tendon-Bone Junction. *J Korean Orthop Assoc* 42: 115-124.
21. Bösch, P, Hertz H, Lintner F, Nowotny R (1981) Beschleunigt das Fibrinklebesystem (FKS) die Heilungsvorgänge von Sehngewebe?. *Arch Orth Traum Surg* 98: 305-310.
22. Thermann H, Frerichs O, Holch M, Biewener A (2002) Healing of Achilles Tendon, An Experimental Study: Part 2-Histological, Immunohistological and Ultrasonographic Analysis. *Foot & Ankle International* 23: 606-613.
23. Winter U (1985) Versorgung frischer Achillessehnenrupturen mit dem Fibrin-Kleber [Treatment of fresh Achilles tendon ruptures with fibrin glue]. *Aktuelle Traumatol* 219-221.
24. Haas F, Haiböck H, Reindl P (1987) Achillessehnenklebung mit Fibrinkleber [Gluing of the Achilles tendon with a fibrin adhesive]. *Zentralbl Chir* 112: 99-104.
25. Paar O, Bernett P (1984) Therapie der Achillessehnen-Ruptur beim Sportler. Vorteile der Fibrinklebung [Therapy of Achilles tendon rupture in athletes. Advantages of fibrin gluing]. *Fortschr Med* 22: 1106-1108.
26. Sterkers O, Becherel P, Sterkers JM (1989) Réparation du nerf facial par colle de fibrine exclusive 56 cas [Repair of the facial nerve exclusively by fibrin glue. 56 cases]. *Ann Otolaryngol Chir Cervicofac* 106: 176-181.
27. Lusardi DA, Cain JE (1994) The effect of fibrin sealant on the strength of tendon repair of full thickness tendon lacerations in the rabbit Achilles tendon. *J Foot Ankle Surg* 33: 443-447.
28. He M, Gan AWT, Lim AYT, Goh JCH, Goh JHP, et al. (2013) The effect of fibrin glue on tendon healing and adhesion formation in a rabbit model of flexor tendon injury and repair. *J Plast Surg Hand Surg*, 47: 509-512.
29. Kim H, Kang S, Lim H, Han S, Lee J (2007) The Role of Transforming Growth Factor- β and Bone Morphogenetic Protein with Fibrin Glue in Healing of Bone-Tendon Junction Injury. *Connect Tissue Res* 48: 309-315.
30. Zhu J, Shao J, Chen Y, Zhao G, Li L (2021) Fibrin Glue-Kartogenin Complex Promotes the Regeneration of the Tendon-Bone Interface in Rotator Cuff Injury. *Stem Cells International*, 2021: 1-8.
31. Bernd Hohendorff, Wolf Siepen, Liesbeth Spiering, Lukas Staub, Thilo Schmuck, et al. (2008) Long-term Results after Operatively Treated Achilles Tendon Rupture: Fibrin Glue versus Suture. *J Foot Ankle Surg* 47: 392-409.
32. Evans CH, Chevalier X, Wehling P (2016) Autologous Conditioned Serum. *Phys Med Rehabil Clin N Am* 27: 893-908.
33. Wehling P, Moser C, Frisbie D, McIlwraith CW, Kawcak CE, et al. (2007) Autologous conditioned serum in the treatment of orthopedic diseases: the orthokine therapy. *BioDrugs* 21: 323-332.
34. Meijer H, Reinecke J, Becker C, Tholen G, Wehling P (2003) The production of anti-inflammatory cytokines in whole blood by physicochemical induction. *Inflamm Res* 52: 404-407.
35. Wehling P, Moser C, Reinecke JA (2009) Use of Autologous Conditioned Cell-free Serum (Orthokine®) in Treating Osteoarthritis and Sciatic Back Pain. *Eur Musculoskelet* 105: 169-184.

36. ACS/BCS alleviates neuropathic pain in spinal conditions such as radiculopathies and intra discal pain (Moser, C., et al. "464 Intradiscal Injections Of Orthokine-Derived Autologous Conditioned Serum (ACS) For Lumbar Disc Degeneration." *Osteoarthritis and Cartilage* 1.19 (2011): S215. Doi:10.1016/S1063-4584(11)60491-3
37. Becker C, Heidersdorf S, Drewlo S, de Rodriguez SZ, Krämer J, et al. (2007) Efficacy of epidural perineural injections with autologous conditioned serum for lumbar radicular compression: an investigator-initiated, prospective, double-blind, reference-controlled study. *Spine (Phila Pa 1976)* 32: 1803-1808.
38. Godek P (2016) Use of Autologous Serum in Treatment of Lumbar Radiculopathy Pain. *Pilot Study. Ortop Traumatol Rehabil* 18: 11-20.
39. Godek P, Szajkowski S, Golicki D (2020) Evaluation of the Effectiveness of Orthokine Therapy: Retrospective Analysis of 1000 Cases. *Ortop Traumatol Rehabil.* 22: 107-119.
40. Baltzer AWA, Moser C, Jansen SAA, Krauspe R (2009) Autologous conditioned serum (Orthokine) is an effective treatment for knee osteoarthritis. *Osteoarthr Cartil. Elsevier Ltd* 17: 152-160.
41. Baselga García-Escudero J, Miguel Hernández Trillos P (2015) Treatment of Osteoarthritis of the Knee with a Combination of Autologous Conditioned Serum and Physiotherapy: A Two-Year Observational Study. *PLoS One.* 28: e0145551.
42. Hashemi M, Taheri M, Adkhoo H, Dadkhah P, Abbasian MR (2019) Comparison of The Effect of Intra-Articular Injection of Autologous (Orthokine) Interleukin-1 (IL-1Ra) Receptor Antagonist and Hyaluronic Acid in Pain Control of Knee Osteoarthritis. *Nov Biomed* 7: 210-217.
43. Simon MJK, Aartsen VE, Coghlan JA, Strahl A, Bell SN (2021) Shoulder injections with autologous conditioned serum reduce pain and disability in glenohumeral osteoarthritis: longitudinal observational study. *ANZ J Surg* 91: 673-679.
44. Oc Y (2017) Autologous conditioned serum treatment in the knee osteoarthritis. *Ann Eurasian Med.* 5:17-21.
45. Pishgahi A, Abolhasan R, Shakouri SK, Soltani-Zangbar MS, Dareshiri S, et al. (2020) Effect of Dextrose Prolotherapy, Platelet Rich Plasma and Autologous Conditioned Serum on Knee Osteoarthritis: A Randomized Clinical Trial. *Iran J Allergy, Asthma Immunol* 19: 243-252.
46. Blázquez R, Sánchez-Margallo FM, Reinecke J, Álvarez V, López E (2019) Conditioned Serum Enhances the Chondrogenic and Immunomodulatory Behavior of Mesenchymal Stem Cells. *Front Pharmacol* 28; 10:699.
47. Wright-Carpenter T, Klein P, Schäferhoff P, Appell HJ, Mir LM, et al. (2004) Treatment of muscle injuries by local administration of autologous conditioned serum: a pilot study on sportsmen with muscle strains. *Int J Sports Med* 25: 588-593.
48. Majewski M, Ochsner PE, Liu F, Flückiger R, Evans CH (2009) Accelerated healing of the rat Achilles tendon in response to autologous conditioned serum. *Am J Sports Med.* 37: 2117-2125.
49. Genç E, Beytemur O, Yuksel S, Eren Y, Çağlar A, et al. (2018) Investigation of the biomechanical and histopathological effects of autologous conditioned serum on healing of Achilles tendon. *Acta Orthop Traumatol Turc.* 52: 226-231.
50. Darabos N, Hundric-Haspl Z, Haspl M, Markotic A, Darabos A, et al. (2009) Correlation between synovial fluid and serum IL-1beta levels after ACL surgery-preliminary report. *Int Orthop* 33: 413-418.
51. Shirokova L, Noskov S, Gorokhova V, Reinecke J, Shirokova K (2020) Intra-articular injections of a whole blood clot secretome, autologous conditioned serum, have superior clinical and biochemical efficacy over platelet-rich plasma and induce rejuvenation-associated changes of joint metabolism: A Prospective, Controlled Open label clinical study. *Rejuvenation Res* 23: 401-410.
52. Darabos N, Haspl M, Moser C, Darabos A, Bartolek D, et al (2011) Intraarticular application of autologous conditioned serum (ACS) reduces bone tunnel widening after ACL reconstructive surgery in a randomized controlled trial. *Knee Surg Sports Traumatol Arthrosc* S1: S36-46.
53. Buchheit T, Huh Y, Maixner W, Cheng J, Ji R-R (2020) Neuroimmune modulation of pain and regenerative pain medicine. *J Clin Invest* 130: 2164-2176.
54. Prapto D, Tertea C, Purvance I (2020) Neuropathic Pain Component Insights in Patients with Knee Osteoarthritis: An Observational Study. *Orthop J Sports Med* 8: (5 suppl5).
55. Thakur, M., Dickenson, A. & Baron, R (2014) Osteoarthritis pain: nociceptive or neuropathic?. *Nat Rev Rheumatol* 10: 374 -380.
56. Ohtori S, Orita S, Yamashita M, Ishikawa T, Ito T, et al. (2012) Existence of a neuropathic pain component in patients with osteoarthritis of the knee. *Yonsei Med J* 53: 801-805.
57. Dimitroulas T, Duarte RV, Behura A, Kitas GD, Raphael JH (2014) Neuropathic pain Dimitroulas T, Duarte RV, Behura A, Kitas GD, Raphael JH (2014) Neuropathic pain in osteoarthritis: a review of pathophysiological mechanisms and implications for treatment. *Semin Arthritis Rheum* 44: 145-154.
58. Lin Y, Zhang K, Li Q (2019) Innervation of nociceptors in intact human menisci along the longitudinal axis: semi-quantitative histological evaluation and clinical implications. *BMC Musculoskelet Disord* 20 : 338.
59. Roubille C, Raynauld JP, Abram F, Paiement P, Dorais M, et al. (2014) The presence of meniscal lesions is a strong predictor of neuropathic pain in symptomatic knee osteoarthritis: a cross-sectional pilot study. *Arthritis Res Ther* 16: 507.